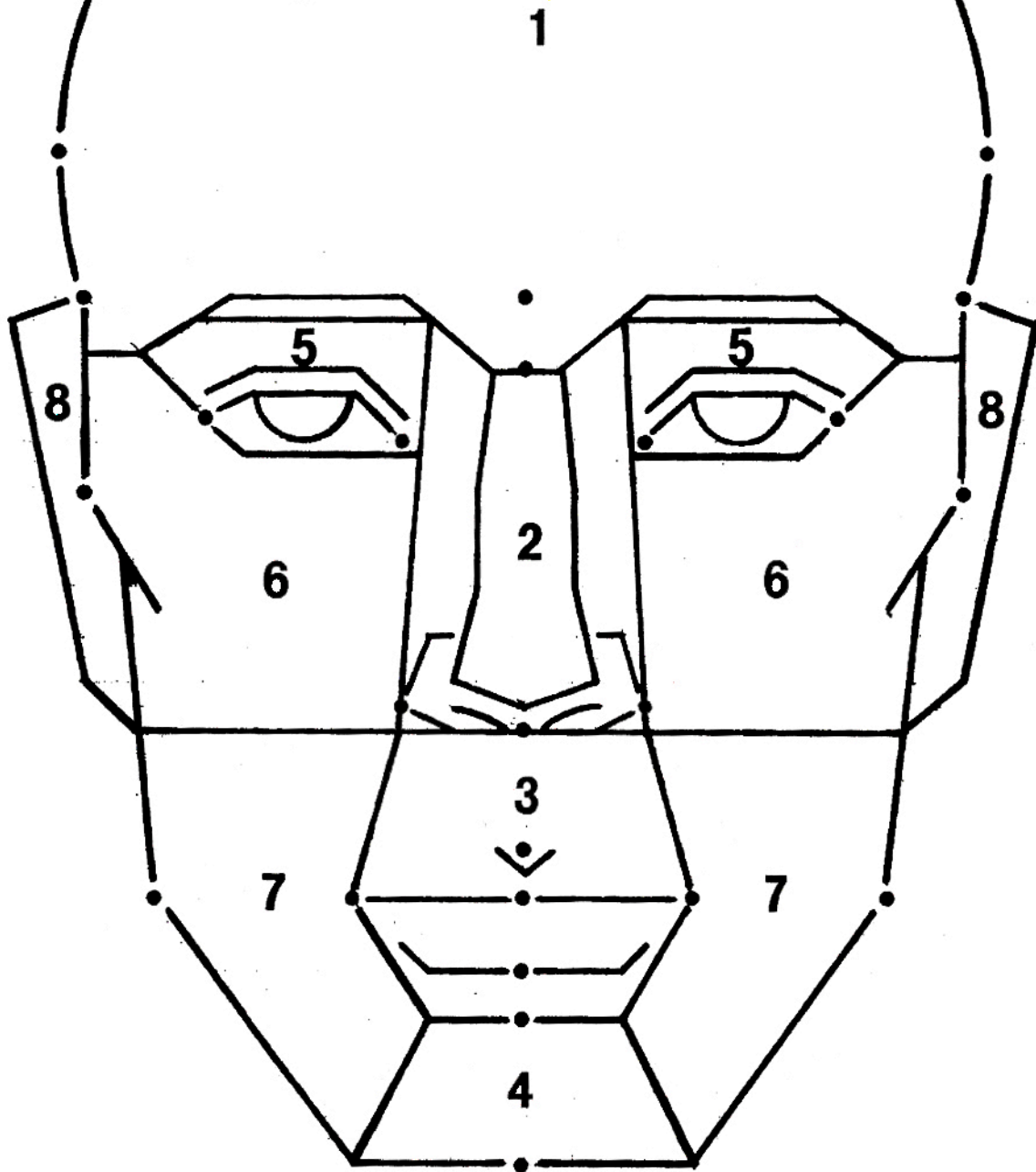


EXCHANGE OF FACE

change is beauty



Presented by Katharine Shutt

EXCHANGE OF FACE

The Next Step



Sample A:
Front View

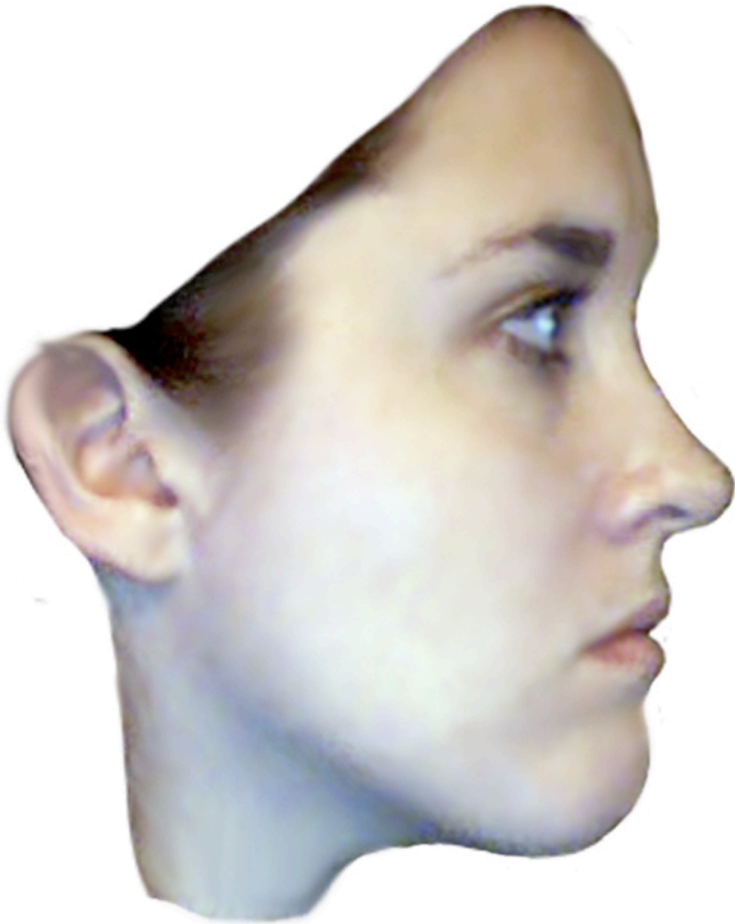

Sample B:
Front View

The objective of this experiment is to successfully merge selected portions of two live faces. This is the first attempt to perform two simultaneous facial-exchange transplants.

EXCHANGE OF FACE

Cosmetic Transplant



Sample A:
Profile View

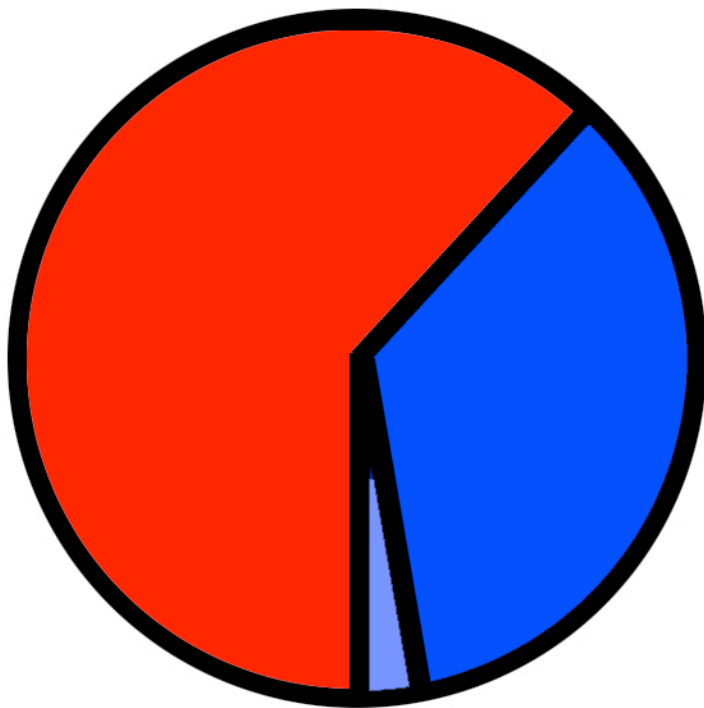


Sample B:
Profile View

The two willing specimens participating in this experiment will have the lower portion of their face, cut just below the nose and containing the lips, chin, and right cheek. These skin tissue samples will be exchanged for the other.

EXCHANGE OF FACE

Lifelong Decision

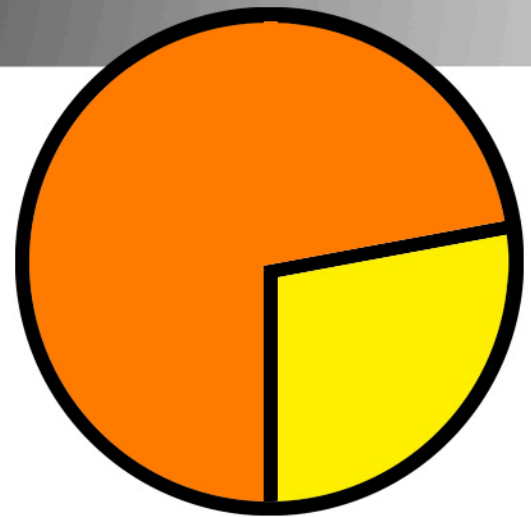


A: Success Rate of Surgeries

63% Successful Transplants

37% Failed Transplants

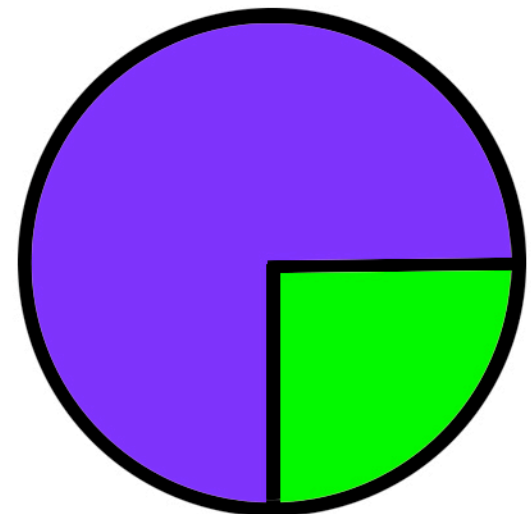
8% Mortality Rate



B: Relationships of Successful Transplants

70% Stayed Together Post-Transplant

30% Split Apart Post-Transplant



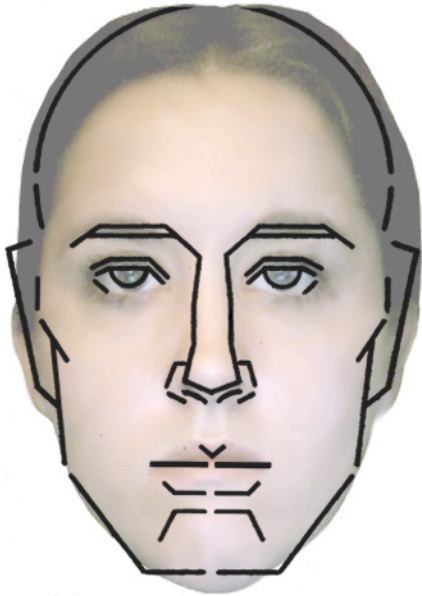
C: Relationships of Failed Transplants

74% Split Apart Post-Transplant

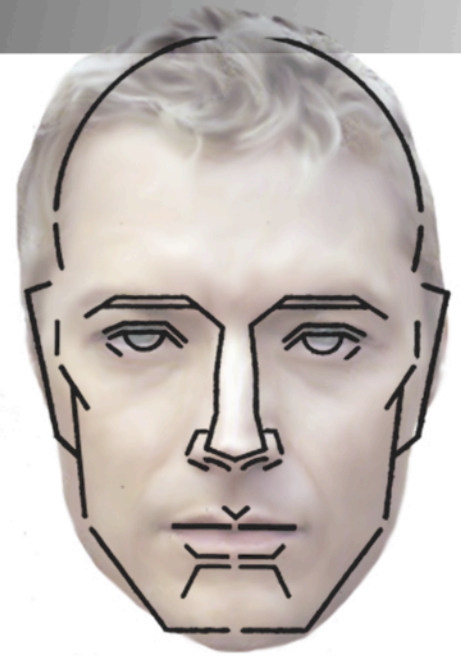26% Stayed Together Post-Transplant

EXCHANGE OF FACE

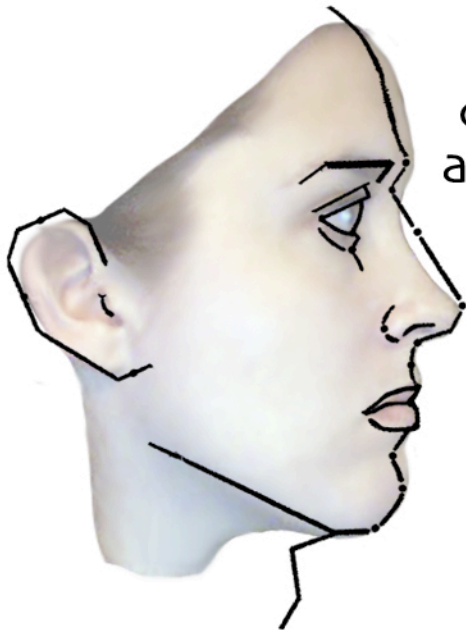The Perfect Match



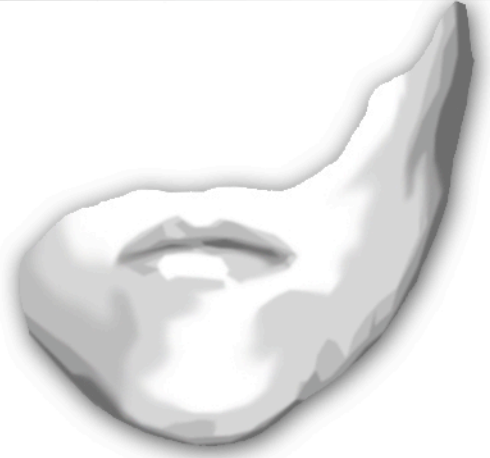
To accurately match the geometric discrepancies of each facial structure, precise measurements are made and compared.



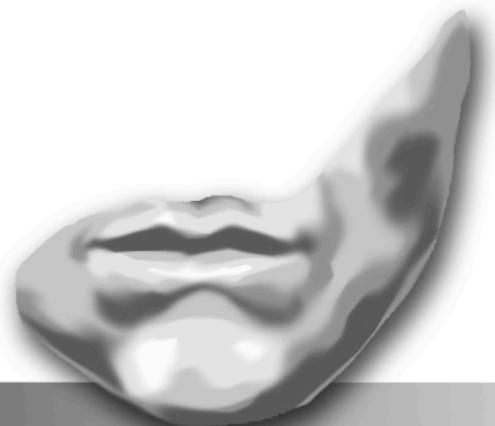To aid in the comfort of merging these facial samples to the face, extra fat and flesh from fresh cadavers may be used as filler in some places.



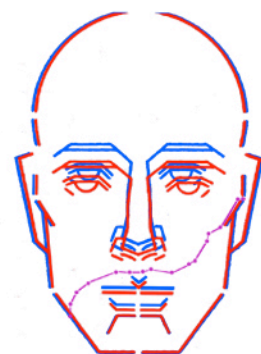
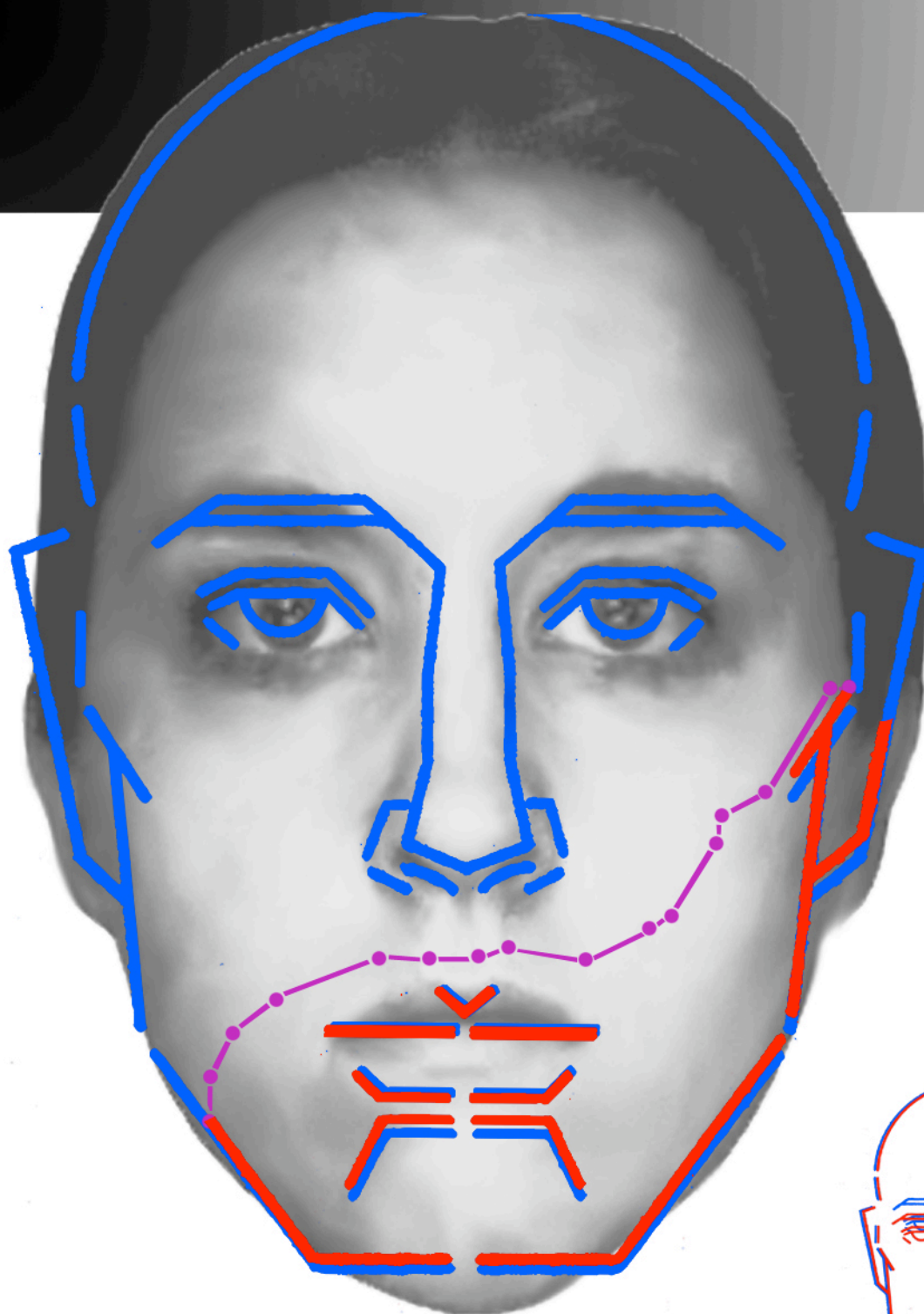
EXCHANGE OF FACE



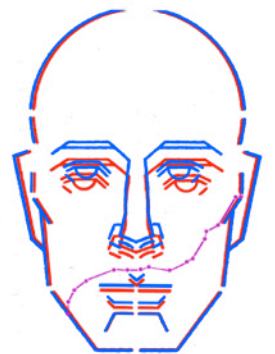
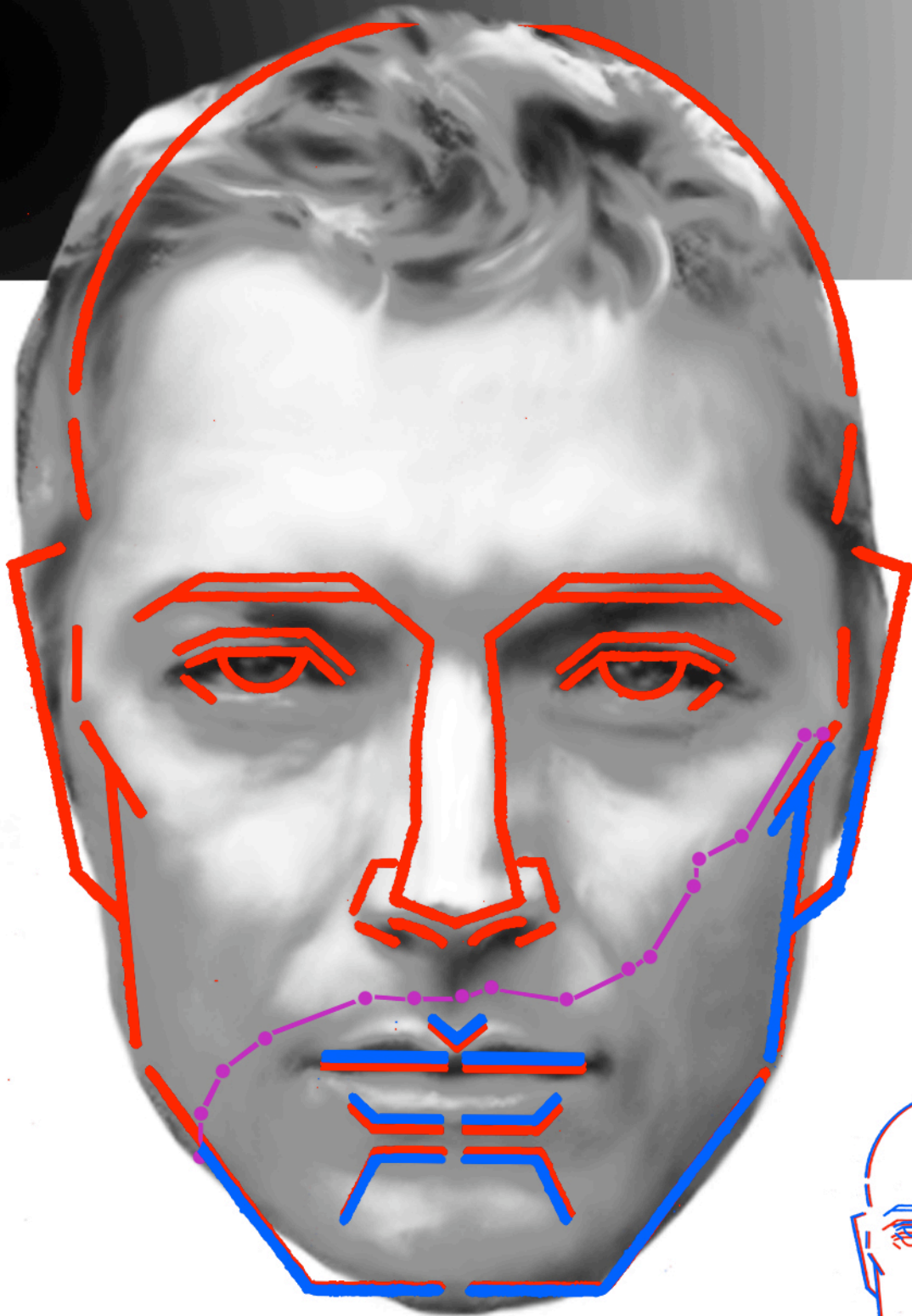
In order to make accurate and tangible assessments regarding the facial positioning, a computer-generated program creates a digital map of each specimen's entire face and the portion being removed.



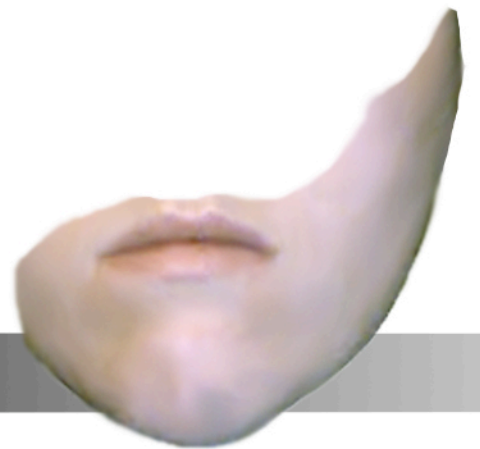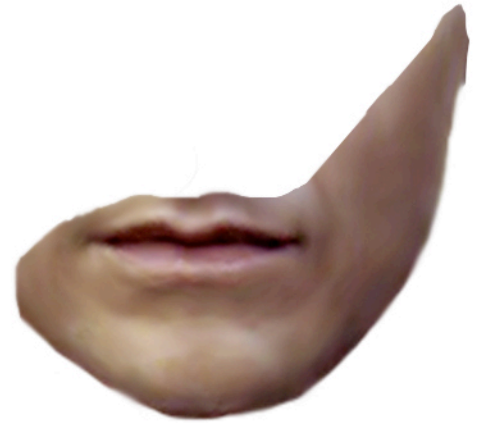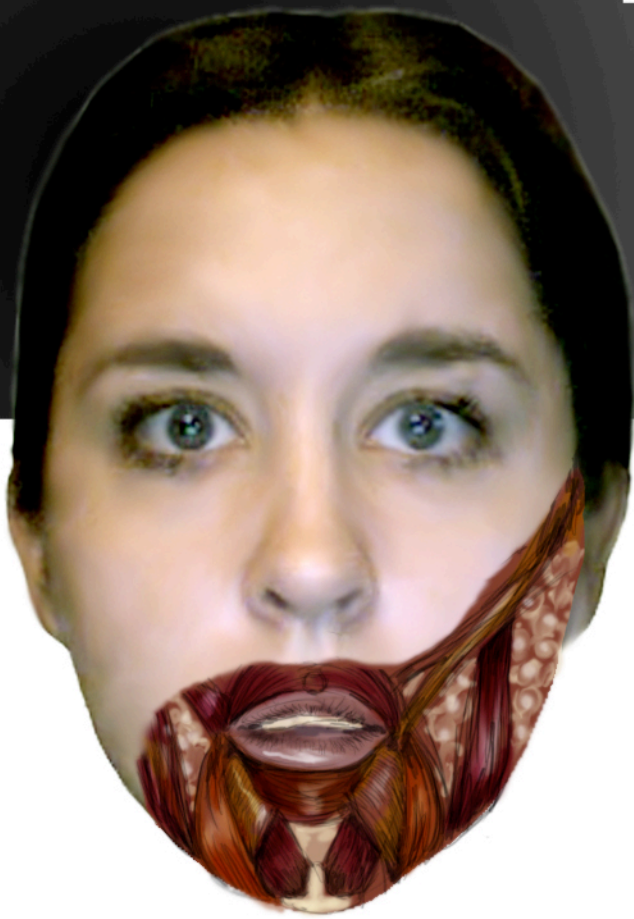EXCHANGE OF FACE

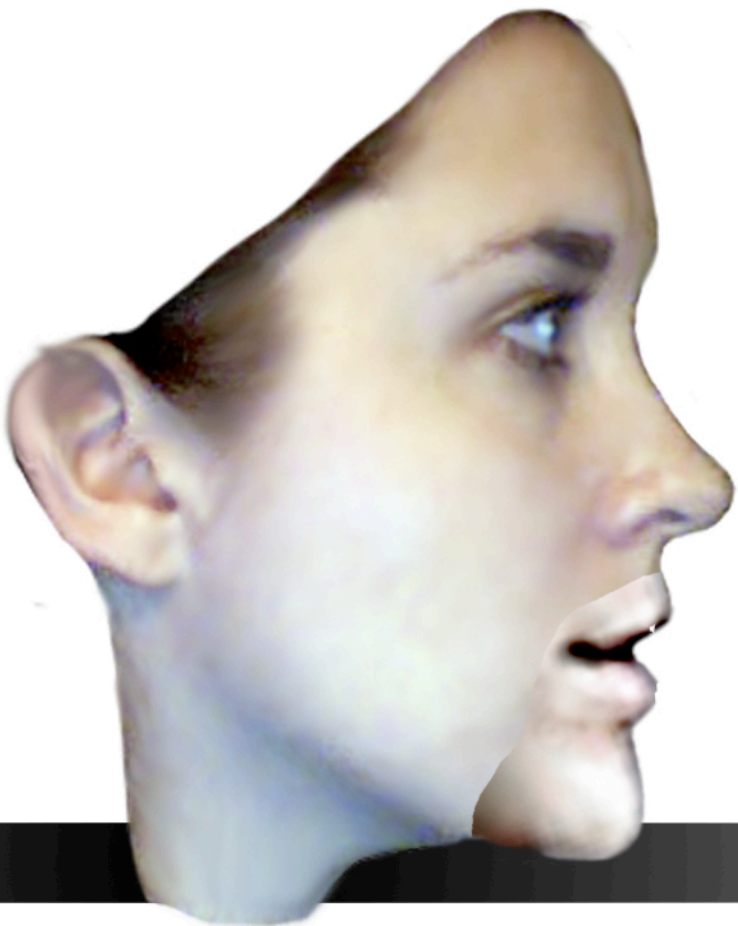


EXCHANGE OF FACE



EXCHANGE OF FACE





EXCHANGE OF FACE

Healing Process



3 months after the transplant.

The healing process that follows this procedure is very slow, and should be taken very seriously. At least six weeks bed rest is required for all patients, and it is recommended that each patient go on extended sick leave from work or school, for at least 15 weeks.

This couple is healing very nicely; you'll notice that the male (Sample B) can already smile, albeit very stiffly. The female (Sample A) has some trouble, but is adjusting well enough to make use of her cheek muscles.

It is very important that each patient look into therapy sessions with EXCHANGE OF FACE's suggested psychiatric help. After the acquisition of a new face, it is understandable--even expected--that it would take time getting used to.

EXCHANGE OF FACE



After one year of healing and corrective surgery,
SUCCESS!

Special Thanks go to
Chris Botti, who has no
idea I've appropriated his
image onto my face most
inappropriately.





EXCHANGE OF FACE

An example of a face-exchange between different face shapes and skin types, after 2 months of healing.

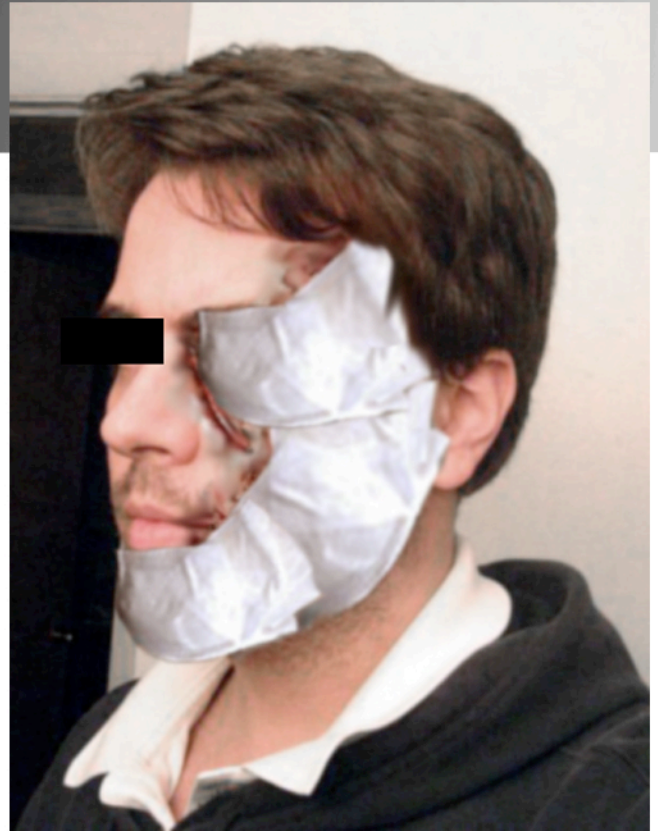

EXCHANGE OF FACE

Surgical Problems



Example A



Example B

There are many considerations to be taken into account before submitting oneself to the EXCHANGE OF FACE surgical procedure. Aside from the obvious question as to whether one would actually want to permanently affix the face of another onto ones face, there are also the serious medical issues that may surface during and after the surgery has transpired.

In the case of Example A, the females flesh did not properly accept the facial portion. The flesh quickly began to decay, and needed to be treated immediately with a silicone-based solution that permanently froze the piece in place, as you can see by the stiff discoloration.

The subjects flesh in Example B did not take to the transplanted sample at all. As a result, he is confined to bed rest for an indeterminant amount of time, as the wound leaves him very vulnerable to infection.

It is likely that he will remain permanently deformed.